



Adam N. Whatley, M.D.
6550 Main St., STE. 2300
Zachary, LA 70791
Phone(225)658-1808 Fax(225)658-5299

Reverse Total Shoulder Arthroplasty with Latissimus dorsi tendon transfer Protocol:

General Information:

Reverse or Inverse Total Shoulder Arthroplasty (rTSA) is designed specifically for the treatment of glenohumeral (GH) arthritis when it is associated with irreparable rotator cuff damage, complex fractures as well as for a revision of a previously failed conventional Total Shoulder Arthroplasty (TSA) in which the rotator cuff tendons are deficient.

The rTSA prosthesis reverses the orientation of the shoulder joint by replacing the glenoid fossa with a glenoid base plate and glenosphere and the humeral head with a shaft and concave cup. This prosthesis design alters the center of rotation of the shoulder joint by moving it medially and inferiorly. This subsequently increases the deltoid moment arm and deltoid tension, which enhances both the torque produced by the deltoid as well as the line of pull / action of the deltoid. This enhanced mechanical advantage of the deltoid compensates for the deficient RC as the deltoid becomes the primary elevator of the shoulder joint. This results in an improvement of shoulder elevation and often individuals are able to raise their upper extremity overhead.

Outcomes for patients following rTSA with teres minor deficiency have been significantly limited in terms of active external rotation, particularly with shoulder elevation. Typically individuals with an intact teres minor have a mean of 15 degrees improvement of active external rotation following rTSA yet individuals who have a deficient teres minor demonstrate no improvement of active external rotation postoperatively. Therefore, in cases where the teres minor is deficient or absent a surgeon may elect to perform a latissimus dorsi tendon transfer (LDTT) to compensate for the teres minor deficiency. The latissimus dorsi muscle is well suited to transfer for several reasons, including its large surface area, strength, and good vascularization. All of these factors are important when considering how this muscle will recover following surgery, particularly the muscle's vascularity as an adequate supply of nutrients is essential for the healing processes to occur.

The mechanics of the shoulder complex following rTSA with a LDTT are, as expected, different from a native shoulder. For example, in its normal anatomical position, the latissimus dorsi muscle acts as an extensor of the humerus, yet after being transferred it becomes a humeral head

stabilizer creating an external rotation moment around the rTSA components. This conversion to a humeral head stabilizer and external rotator is important as it now allows the joint to function more efficiently as it compensates for the actions of the deficient teres minor. The biomechanics of the postoperative shoulder allow for more effective action of the deltoid, which is important during various daily activities that incorporate elevation and abduction movements.

The rotator cuff is absent with the rTSA and LDTT; therefore, the rehabilitation for a patient following the rTSA and LDTT is different than the rehabilitation following a traditional TSA. The surgeon, physical therapist and patient need to take this into consideration when establishing the postoperative treatment plan. Important rehabilitation management concepts to consider for a postoperative physical therapy rTSA and LDTT program are:

- Joint protection: There is a higher risk of shoulder dislocation following rTSA and LDTT when compared to a conventional TSA.
 - Patients following a rTSA with LDTT do not dislocate with the arm in abduction and external rotation. They will typically dislocate with the arm in internal rotation and adduction in conjunction with extension. For example, tucking in a shirt or performing bathroom / personnel hygiene with the operative arm is a dangerous activity particularly in the immediate peri-operative phase.
 - Avoidance of shoulder extension beyond neutral with the combination of shoulder adduction and internal rotation for a minimum of 12 weeks postoperatively.
 - It is important to avoid over stretching or putting excessive tension on the healing transferred latissimus dorsi tendon. No aggressive internal rotation, flexion, or adduction is advised.
- Deltoid function: Stability and mobility of the shoulder joint is now dependent upon the deltoid and periscapular musculature. This concept becomes the foundation for the postoperative physical therapy management for a patient following rTSA with LDTT.
- Function: As with a conventional TSA, maximize overall upper extremity function, while respecting soft tissue constraints.
- ROM: Expectation for range of motion gains should be set on a case-by-case basis depending upon underlying pathology. Normal/full active range of motion of the shoulder joint following rTSA with a LDTT is not expected.

Figure 1. Anterior Posterior radiograph (A) and illustration (B) of a left shoulder with rotator cuff arthropathy. The superiorly migrated humeral head indicates rotator cuff deficiency.

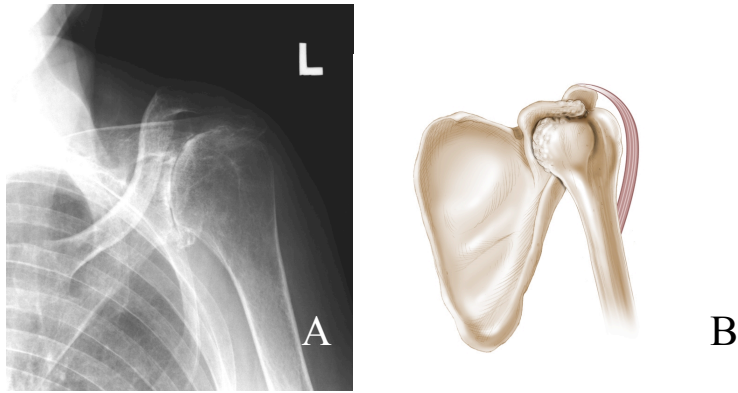
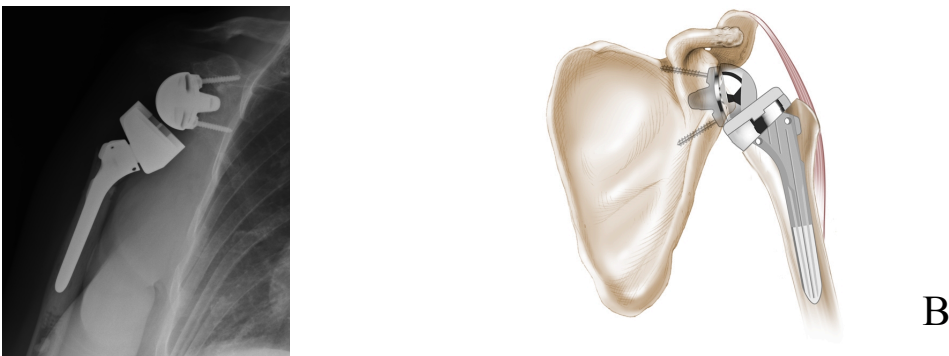

Figure 2. Reverse Total Shoulder Arthroplasty Components (Zimmer, Warsaw, IN). The prosthesis has 5 parts: the glenoid base, the glenosphere, a polyethylene cup, humeral neck, and the humeral stem.



Figure 3. Anterior Posterior radiography of a right shoulder (A) and an illustration of a left shoulder (B) after reverse total shoulder arthroplasty.



Reverse Total Shoulder Arthroplasty with Latissimus Dorsi Tendon Transfer Protocol:

The intent of this protocol is to provide the physical therapist with a guideline/treatment protocol for the postoperative rehabilitation management for a patient who has undergone a Reverse Total Shoulder Arthroplasty (rTSA) with latissimus dorsi tendon transfer (LDTT). It is by no means intended to be a substitute for a physical therapist's clinical decision making and should be based on the individual patient's physical exam/findings, progress, and/or the presence of postoperative complications. If the physical therapist requires assistance in the progression of a postoperative patient who has had rTSA and LDTT the therapist should consult with the referring surgeon.

The **scapular plane** is defined as the shoulder positioned in 30 degrees of abduction and forward flexion with neutral rotation. ROM performed in the scapular plane should enable appropriate shoulder joint alignment.

Shoulder Dislocation Precautions:

- **No shoulder motion behind the patient's back. (NO combined shoulder adduction, internal rotation, and extension.)**
- **No glenohumeral (GH) extension beyond neutral.**

*Precautions should be implemented for 12 weeks postoperatively unless the surgeon specifically advises patient or therapist differently.

Surgical Considerations:

- The surgical approach needs to be considered when devising the postoperative plan of care.
- Traditionally rTSA with LDTT procedure is performed via a typical lengthened deltopectoral approach, which minimizes surgical trauma to the anterior deltoid and exposes the latissimus dorsi tendon. The latissimus dorsi tendon is identified, after releasing the pectoralis major tendon while protecting the radial and axillary nerve. The latissimus dorsi is then mobilized and pulled around the posterior aspect of the humeral head and attached to the greater tuberosity region of the humerus.
- The start of this protocol is typically delayed 2-4 weeks following rTSA with LDTT in a revision situation and/or in the presence of poor bone stock based on the surgeon's assessment of the integrity of the surgical repair.

***Progression of phases is based on clinical criteria and timeframes as appropriate.**

Phase I – Immediate Post Surgical Phase/Joint Protection (Day 1-6 weeks):

Phase I ADL's
<ul style="list-style-type: none">• Avoid all activities using operative upper extremity for first 4 weeks except for those done with the physical therapist.• Clothing: Oversized button down shirts, women should avoid wearing bras for the first 4wks

Goals:

- Patient and family independent with:
 - Joint protection
 - Assisting with putting on/taking off gunslinger or ER sling and clothing
 - Cryotherapy
- Promote healing of soft tissue / maintain the integrity of the replaced joint and transferred tendon.
- Restore active range of motion (AROM) of elbow/wrist/hand.
- Independent with bed mobility, transfers and ambulation or as per pre-admission status. (NWB for this extremity)

Phase I Precautions:

- Patient is immobilized in an at least neutral to 15 degrees of external rotation in the plane of the scapula to keep the transferred tendon in a shortened protected position to enhance healing. They is either done with a gunslinger or an external rotation sling, per MD recommendation.
- While lying supine, the distal humerus/ elbow should be supported by a pillow or towel roll to avoid shoulder extension. Patients should be advised to “always be able to visualize their elbow while lying supine.”
- No shoulder AROM or passive range of motion (PROM).
- No lifting of objects with operative extremity.
- No supporting of body weight with involved extremity.
- Keep incision clean and dry (no soaking/wetting for 2 weeks); No whirlpool, Jacuzzi, ocean/lake wading for 4 weeks.

Acute Care Therapy (Day 1 to 4):

- Active/Active Assisted ROM (A/AAROM) of cervical spine, elbow, wrist, and hand.
- Begin periscapular sub-maximal pain-free isometrics in the scapular plane.
- Continuous cryotherapy for first 72 hours postoperatively, then frequent application (4-5 times a day for about 20 minutes).
- Insure patient is independent in bed mobility, transfers and ambulation
- Insure proper gunslinger fit/alignment/ use.
- Instruct patient in proper positioning, posture, initial home exercise program.
- Provide patient/ family with written home program including exercises and protocol information.

Day 5 to 28:

- Patient continues all exercises as above at home.
- Frequent (4-5 times a day for about 20 minutes) cryotherapy.

4 Weeks to 6 Weeks:

- Patient typically begins formal outpatient physical therapy.
- Progress exercises listed above.
- Begin sub-maximal pain-free deltoid isometrics in scapular plane (avoid shoulder extension when isolating posterior deltoid.)
- Begin shoulder PROM:
 - Forward flexion and elevation in the scapular plane in supine to 120 degrees as tolerated.
 - NO IR PROM at this time.
 - ER in scapular plane to tolerance, respecting soft tissue constraints (typically 30-40 degrees of ER).
- Continue frequent cryotherapy.

Criteria for progression to the next phase (Phase II):

- Tolerates shoulder PROM and deltoid isometrics; and AROM program for elbow, wrist, and hand.

- Patient demonstrates the ability to isometrically activate all components of the deltoid and periscapular musculature in the scapular plane.

Phase II –Active Range of Motion / Early Strengthening Phase (Week 6 to 12):

<p>Phase II ADL's</p> <ul style="list-style-type: none"> • Independent dressing and showering below 90deg shoulder elevation and with upper extremity in front of patient. • Use caution to prevent jerking motions when don/doffing clothing. • Use of operative arm to eat/drink and perform light activities. • No lifting of objects more than 2-3 pounds with operative upper extremity.

Goals:

- Continue progression of PROM (full PROM is not expected).
- Gradually restore AROM.
- Facilitate latissimus dorsi to function as a humeral head stabilizer and external rotator.
- Control pain and inflammation.
- Allow continued healing of soft tissue / do not overstress healing tissue.
- Re-establish dynamic shoulder and scapular stability.

Precautions:

- If the patient was in a gunslinger they are weaned out of it into and ER sling at post-op week # 6. Goal is to be weaned out of sling by post-op week # 8 if adequate shoulder motor control (i.e. negative ER lag sign and the ability to actively elevate shoulder at least 50 degrees without pain.)
- No forced shoulder ROM
- Restrict lifting of objects to no heavier than a coffee cup.
- No supporting of body weight by involved upper extremity.

Week 6 to Week 8:

- Continue with PROM program.
 - At 6 weeks post op start PROM IR to tolerance (not to exceed 30 degrees) in the scapular plane.
- Begin Active assisted range of motion (AAROM) and AROM (Begin in supine and sidelying then progress to antigravity positions as appropriate)
 - Forward Flexion (lawn chair progression) *
 - Forward elevation *
 - External Rotation *
 - Internal Rotation

***Use of a biofeedback is helpful for visual and auditory feedback to re-educate the Latissimus muscle to function as an external rotator. Neuromuscular electrical stimulation (NMES) is useful to assist in muscular recruitment as well.**

- Initiate gentle scapulothoracic rhythmic stabilization and alternating isometrics in supine as appropriate. Begin gentle periscapular and deltoid sub-maximal pain free isotonic strengthening exercises, typically toward the end of the 8th week.
- Progress strengthening of elbow, wrist, and hand.
- Gentle glenohumeral and scapulothoracic joint mobilizations as indicated (Grade I and II).
- Continue use of cryotherapy as needed.
- Patient may begin to use hand of operative extremity for feeding and light activities of daily living including dressing, washing.

Week 9 to Week 12:

- Continue with above exercises and functional activity progression.
- Begin AROM supine forward flexion and elevation in the plane of the scapula with light weights (1-3lbs. or .5-1.4 kg) at varying degrees of trunk elevation as appropriate. (i.e. supine lawn chair progression with progression to sitting/standing).
- Progress to gentle glenohumeral IR and ER isometric and isotonic strengthening exercises in sidelying position with light weight (1-3lbs or .5-1.4kg) and/or with light resistance resistive bands or sport cords.

Criteria for progression to the next phase (Phase III):

- Improving function of shoulder.
- Patient demonstrates the ability to isotonicly activate all components of the deltoid and periscapular musculature and is gaining strength.

Phase III – Moderate strengthening (Week 12 +)

<p>Phase III ADL's</p> <ul style="list-style-type: none"> • Independent with all ADL's including dressing, showering, eating. • Return to light to moderate activities below shoulder height as tolerated. • No lifting of objects with more than 5 pounds with operative extremity.

Goals:

- Enhance functional use of operative extremity and advance functional activities.
- Enhance shoulder mechanics, muscular strength and endurance.

Precautions:

- No lifting of objects heavier than 2.7 kg (6 lbs) with the operative upper extremity below chest height
- No sudden lifting or pushing activities.

Week 12 to Week 16:

- Continue with the previous program as indicated.
- Progress to gentle resisted flexion, elevation in standing as appropriate.

Phase IV – Continued Home Program (Typically 4 + months postop):

:Phase IV ADL's

- No lifting of objects more than five pounds with operative extremity and 10 pounds with both extremities.
- Progression of light to moderate activities with operative upper extremity within available AROM and with upper extremity in front of body.

- **Typically the patient is on a home exercise program at this stage to be performed 3-4 times per week with the focus on:**
 - Continued strength gains
 - Continued progression toward a return to functional and recreational activities within limits as identified by progress made during rehabilitation and outlined by surgeon and physical therapist.

Criteria for discharge from skilled therapy:

- Patient is able to maintain pain free shoulder AROM demonstrating proper shoulder mechanics. (Typically 90 – 120 degrees of elevation with functional ER of up to 10-15 degrees.)
- Typically able to complete light household and work activities.